

## Unprecedented Challenge: Eight Impacted Ureteric Calculi in a Single Ureter

Dr. Harsh Rajeev Mehta†, Dr. Vinod Joshi

Urology Resident, Hinduja  
Hospital, Mumbai

**Abstract:** The presence of multiple ureteric calculi within a single ureter poses a rare and challenging clinical scenario. We present the case of a 39-year-old male who presented with the uncommon manifestation of eight impacted right-sided ureteric calculi. This case report discusses the diagnostic approach and management considerations for such complex urinary tract stone presentations. The etiology of multiple stones in a single ureter may involve a combination of intrinsic factors such as anatomical anomalies and metabolic disturbances, alongside extrinsic factors including dietary habits and environmental influences. Accurate diagnosis relies on comprehensive imaging modalities such as computed tomography (CT) urography to assess stone number, size and associated complications. Management strategies encompass a tailored approach considering stone composition, patient factors, and anatomical considerations. Minimally invasive techniques such as ureteroscopy with laser lithotripsy or percutaneous nephrolithotomy (PCNL) offer effective stone clearance while preserving renal function.

**Keyword:** Ureteric calculi, urography, computed tomography

**Copyright:** © 2024 The Authors. Published by Publisher. This is an open access article under the CC BY-NC-ND license (<https://creativecommons.org/licenses/by-nc-nd/4.0/>).

**Supplementary information** The online version of this article (<https://doi.org/xx.xxx/xxx.xx>) contains supplementary material, which is available to authorized users.

**Corresponding Author:** Dr. Harsh Rajeev Mehta †, Urology Resident, Hinduja Hospital, Mumbai

## Introduction

Ureteric calculi, commonly known as kidney stones, represent a significant burden on global healthcare systems due to their prevalence and associated morbidity. While the occurrence of a single ureteric calculus is a well-documented phenomenon, the presence of multiple calculi within the ureter presents a unique clinical challenge, often necessitating tailored management strategies to ensure optimal outcomes.

We present the case of a 39-year-old male who presented with the uncommon manifestation of eight impacted right-sided ureteric calculi. The presence of multiple stones within a single ureter poses distinct diagnostic and therapeutic dilemmas, requiring meticulous evaluation and intervention to alleviate symptoms and prevent complications such as obstruction, infection, or renal impairment.

This case underscores the importance of a multidisciplinary approach to the management of complex urological conditions, involving collaboration between urologists, radiologists, and other allied healthcare professionals. Through detailed clinical assessment, judicious diagnostic imaging, and advanced endoscopic techniques, we successfully addressed the challenge posed by the patient's multiple ureteric calculi, ultimately achieving a favorable outcome. By elucidating the diagnostic and therapeutic intricacies encountered in this case, we aim to contribute to the existing body of literature on the management of ureteric calculi, providing insights that may inform future clinical practice and guide optimal patient care.

## Case report

39 year old gentleman presented with chief complaints of severe right sided flank pain, intermittently relieved with analgesics since 1 month with few episodes of associated low grade intermittent fever. There were no complaints of vomiting, dysuria, and hematuria, loss of appetite or weight. Patient has a past history of multiple episodes of lithuria since 2 years. On examination no significant abnormality was noted.

Subsequently further evaluation and workup of this patient was done.

Ultrasonography of abdomen and pelvis was suggestive of right sided mild hydroureteronephrosis with right ureter not well visualised and multiple tiny non obstructing renal calculi. Left sided kidney has small non obstructing calculi.

Serum uric acid levels were high at 7.5. Complete blood count and serum creatinine were within normal limits. Urine culture was sterile with evidence of some rbc's and calcium oxalate crystals. On further evaluation with CT urography, there were multiple calculi in right sided upper, mid and lower ureter with largest size being 8mm in upper ureter and 5mm in lower ureter.

Approximately 5 small non obstructing calculi in right kidney ranging from 4-5mm were noted. Left kidney had multiple non-obstructing calculi in upper and mid calyces, largest being 5mm in size.

Patient was posted for surgery and underwent cystoscopy with right sided ureterorenoscopy with semirigid and flexible ureterorenoscope. Intraoperatively eight ureteric calculi and five ureteric calculi were seen as described in CT scan. Laser lithotripsy was done to pulverise the stones followed by right sided double J stenting. Complete clearance of stones was achieved and patient discharged uneventfully on postoperative day 2. Patient was started on medications for raised uric acid and advised regular follow up for the same.

Three weeks later at follow up patient had complete clearance of right sided ureteric and renal calculi and dj stent was removed.

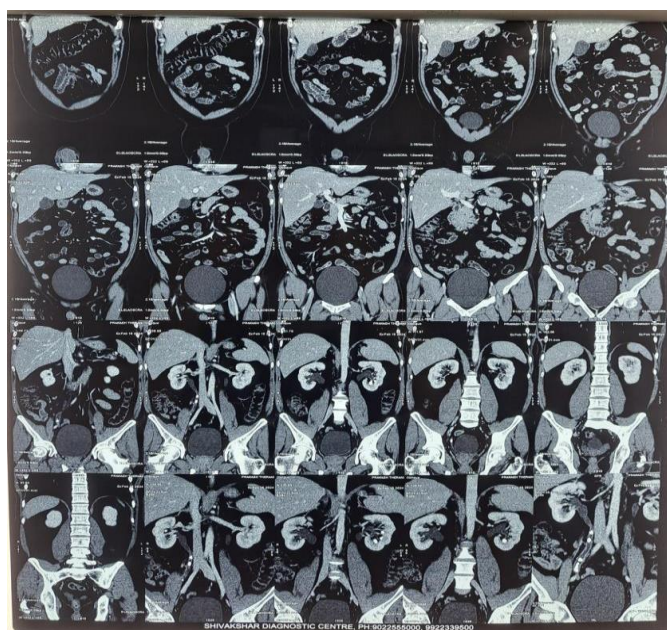


Figure 1- contrast ct of kub region

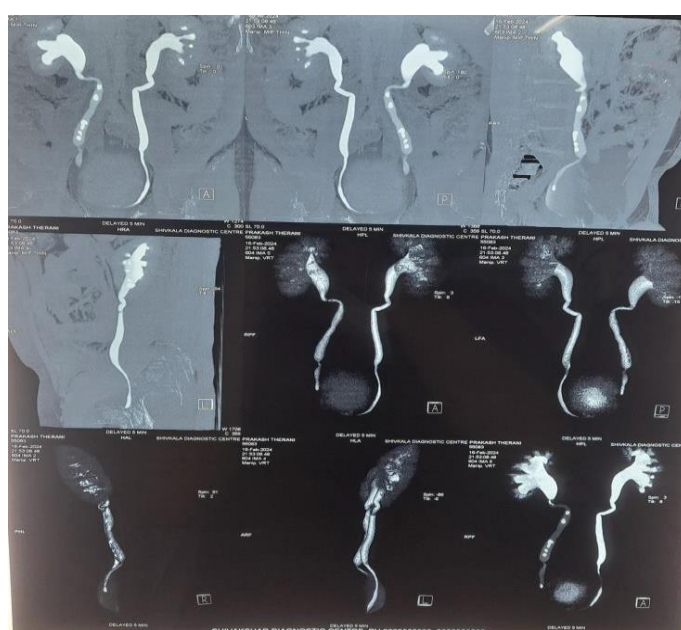
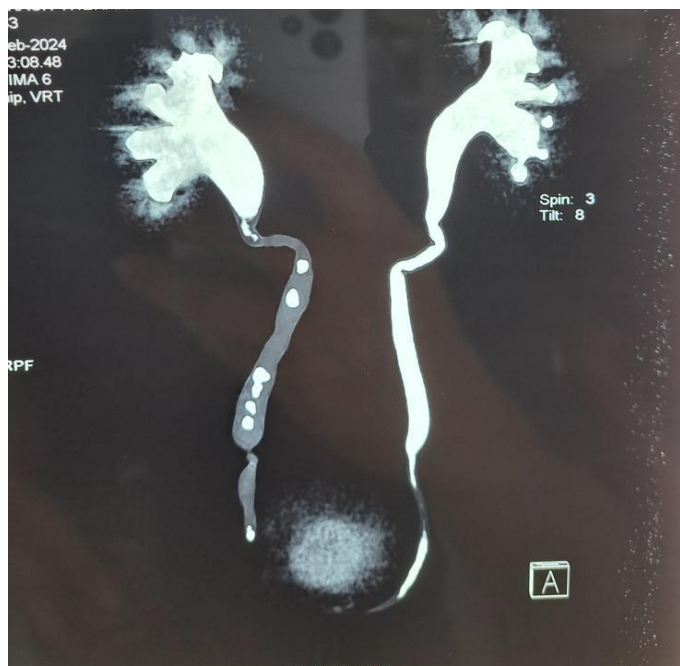
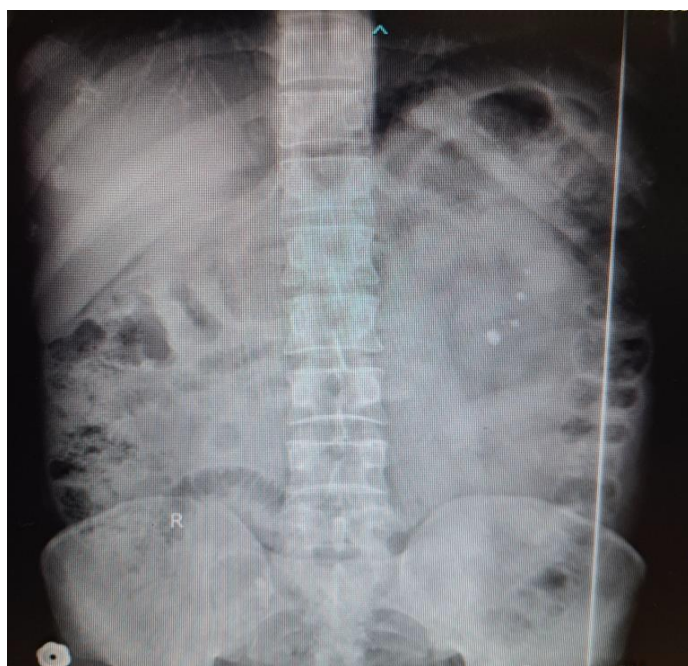


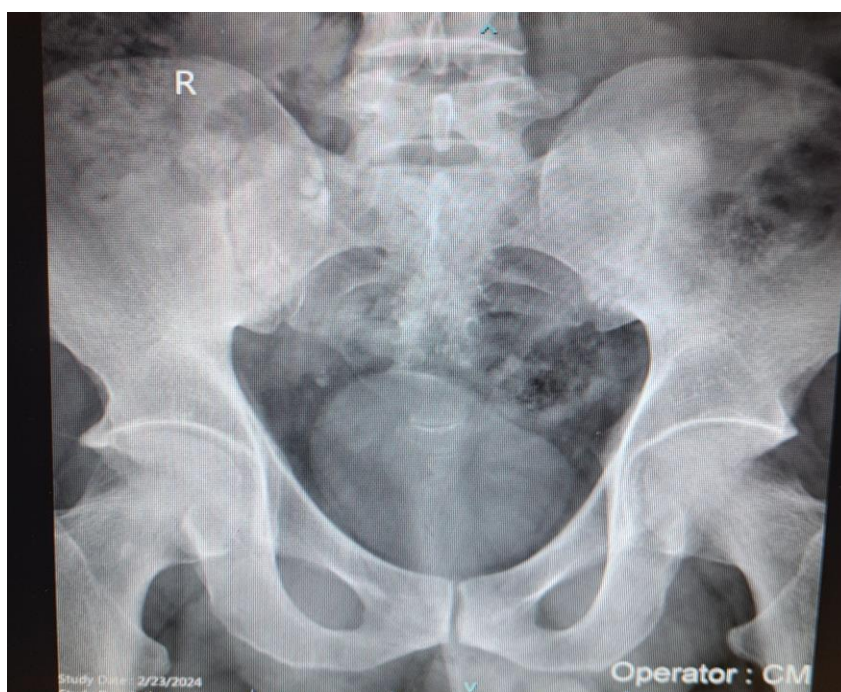
Figure 2



*Figure 3- delayed images on contrast ct scan*



*Figure 4- xray kub image showing stones in both kidneys and right upper ureter*



*Figure 5- xray kub image showing stones in right ureter*

## Discussion

Despite the fact that ureteroscopy is more invasive but less expensive than ESWL in managing distal ureteric stones, ureteroscopy is usually favoured when stones are larger than 10 mm, are known to be cystine, appear radiolucent or possibly occur in women of childbearing age. [1-4]

The presence of eight ureteric calculi within a single ureter presents a rare and challenging clinical scenario. This case prompts discussion on several pertinent aspects of urinary tract stone formation, diagnosis, and management.

Firstly, the etiology of multiple stones in a single ureter may involve a combination of intrinsic factors such as anatomical anomalies, metabolic disturbances, and extrinsic factors including dietary habits and environmental influences. Understanding the underlying causes is crucial for instituting appropriate preventive measures to reduce the risk of recurrence.



Secondly, the diagnostic approach in cases of multiple ureteric calculi necessitates comprehensive imaging modalities such as computed tomography (CT) urography to accurately delineate the number, size, and location of the stones, as well as to assess associated complications such as hydronephrosis or infection.[ 3-7 ]

Thirdly, the management of multiple ureteric calculi requires a tailored approach considering factors such as stone composition, patient's clinical status, and anatomical considerations.

Minimally invasive techniques such as ureteroscopy with laser lithotripsy for ureteric calculi or percutaneous nephrolithotomy (PCNL) for renal calculi may offer effective stone clearance while preserving renal function.

Metabolic evaluation is essential to prevent stone recurrence and optimize long-term outcomes. Further studies and collaborative efforts are warranted to elucidate the underlying mechanisms and refine treatment strategies for such complex cases of urinary tract calculi.

## Conclusion

Despite the rarity and complexity of this case, successful outcomes can be achieved through meticulous surgical planning, advanced imaging techniques, and minimally invasive interventions such as ureteroscopy and laser lithotripsy. Long-term follow-up and surveillance are essential to monitor for stone recurrence and preserve renal function. This case serves as a reminder of the diverse presentations and challenges encountered in urological practice and underscores the importance of continued research and collaboration to enhance our understanding and management of complex urinary tract disorders. In summary, the management of eight ureteric calculi within a single ureter requires a tailored approach, integrating clinical expertise, advanced technologies, and patient-centred care to achieve favourable outcomes and improve quality of life for affected individuals.

## References

1. Chow GK, Patterson DE, Blute ML, Segura JW. Ureteroscopy: effect of technology and technique on clinical practice. *J Urol* 2003; 170: 99–102
2. Lotan Y, Gettman MT, Roehrborn CG, Cadeddu JA, Pearle MS. Management of ureteral calculi: a cost comparison and decision making analysis. *J Urol* 2002; 167: 1621–9
3. Kerbl K, Rehman J, Landman J, Lee D, Sundaram C, Clayman RV. Current management of urolithiasis: progress or regress? *J Endourol* 2002; 16: 281–8
4. Peschel R, Janetschek G, Bartsch G. Extracorporeal shock wave lithotripsy versus ureteroscopy for distal ureteral calculi: a prospective randomized study. *J Urol* 1999; 162: 1909–12
5. Turk TM, Jenkins AD. A comparison of ureteroscopy to *in situ* extracorporeal shock wave lithotripsy for the treatment of distal ureteral calculi. *J Urol* 1999; 161: 45–7
6. Pearle MS, Nadler R, Bercowsky E *et al*. Prospective randomized trial comparing shock wave lithotripsy and ureteroscopy for management of distal ureteral calculi. *J Urol* 2001; 166: 1255–60